

Cystoisospora belli

Basic guidelines

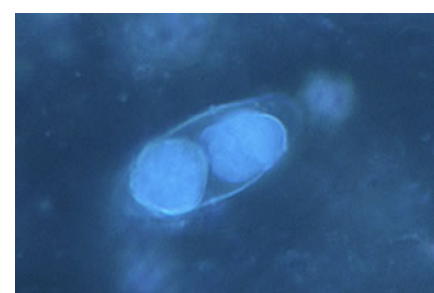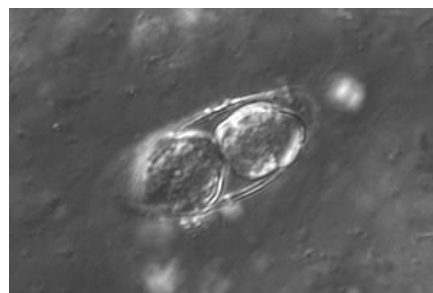
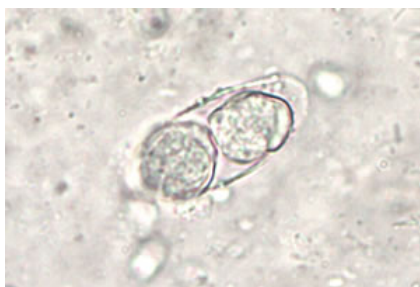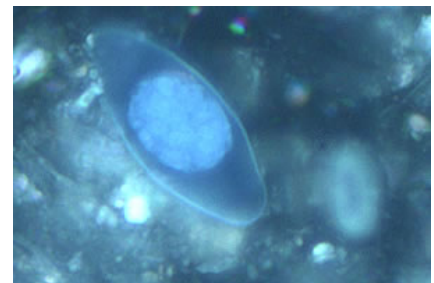
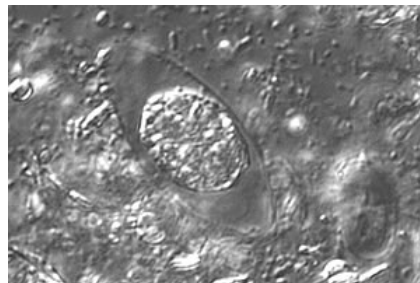
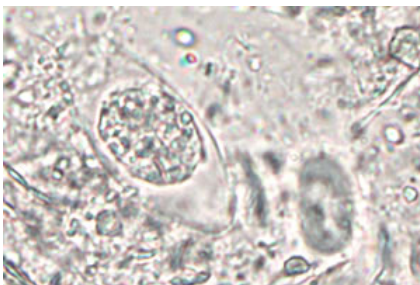
- A. Multiple stool samples (at least 3) should be tested before a negative result is reported.
- B. To maximize recovery of oocysts, stool samples in formalin, or other fixatives, should be concentrated prior to microscopic examination (e.g., 10 min at 500 × g when using the formalin-ethyl acetate concentration procedure).
- C. Choice of diagnostic techniques depends on available equipment and reagents, experience, and considerations of time and cost.

1. Wet mount

Under bright-field microscopy, the oocysts are large (25 to 30 by 10 to 19 μm) and have a typical ellipsoidal shape. Sporulated oocysts containing two sporocysts can be observed if the stool specimen is kept in potassium dichromate at room temperature for more than two days.

Under UV fluorescence microscopy, the oocyst wall autofluoresces. An intense blue fluorescence is obtained with the preferred UV excitation filter set (330 to 365 nm). If this filter set is not available, a less intense green fluorescence can be obtained with blue excitation (450 to 490 nm). Other objects, however, can also autofluoresce. A fluorescence microscope is required and this procedure does not provide a stained slide that can be archived.

Both differential interference contrast (DIC) and UV fluorescence microscopy are efficient and reliable approaches for identification of this coccidian. Objects found by UV microscopy should always be checked under DIC and vice versa.



Wet Mount

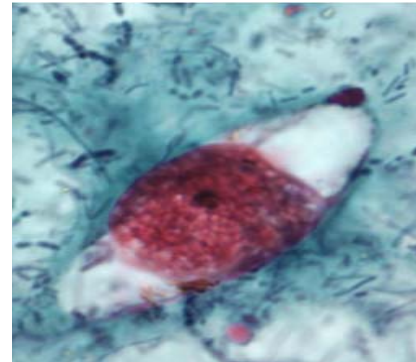
DIC

UV

Key points for laboratory diagnosis of cystoisosporiasis

2. Modified acid-fast stain

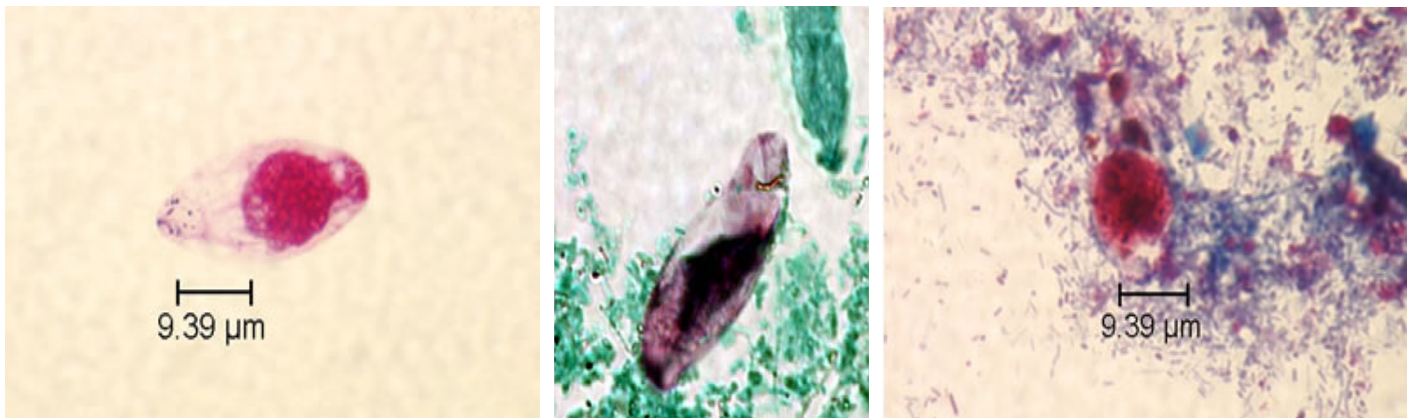
A blue-green background, or contrasting counterstain, of fecal debris allows the oocysts to stand out. They are variably stained: some will stain light pink to deep purple, while others may be unstained. The oocysts (25 to 30 μm) have the typical ellipsoidal shape as shown in the wet mount; their internal structure will not be seen. Some oocysts may appear collapsed or distorted on one side. This staining method is the easiest and most practical, and provides a permanent record.



A *Cystoisospora belli* oocyst stained with the modified acid-fast technique.

3. Safranin stain

Oocysts stain uniformly, red to reddish-orange. The oocysts (25 to 30 μm) will have the typical ellipsoidal shape as in the wet mount; their internal structure may not be seen. Some oocysts may appear collapsed or distorted to one side. This technique requires heating, therefore additional equipment is necessary (e.g., microwave oven).



Cystoisospora belli oocyst stained with safranin stain technique.



SAFER • HEALTHIER • PEOPLE™

